



**PRESENTING CLINICAL SIGNS**

**DATE** History: Murmur, cough, upper respiratory stridor. Radiographs show collapsing trachea vs. redundant tracheal membrane. Recently on doxycycline and temaril-P.

8/1/22

**ECHOCARDIOGRAPHIC FINDINGS**

2D, M-mode, and Doppler study.

**PERFORMED BY:**

Dr. Seth Mitchell

**INTERPRETED BY**

Keith Blass, DVM,  
MS, DACVIM  
(Cardiology)

Left atrial size is normal. The mitral valve leaflets are mildly thickened, and a mild jet of eccentric mitral regurgitation is present. Left ventricular dimensions are normal. Left ventricular systolic function is hyperdynamic. The aorta and aortic valve are normal. Right atrial and right ventricular dimensions are normal. The tricuspid valve is normal. The pulmonary artery and pulmonic valve are normal. No shunting lesions are visualized. No pericardial effusion or cardiac masses are seen.

LA - 24.7 mm  
LVIDd - 24.4 mm  
LVIDs - 12.2 mm  
FS - 50%

**PATIENT**

Stitch Labanowitz

RA - 15.1 mm  
LVOT - 1.78 m/s  
RVOT - 1.26 m/s

**ASSESSMENT/RECOMMENDATIONS**

Degenerative mitral valve disease

**SPECIES**

Canine

This examination demonstrates mild regurgitation of blood across Stitch's mitral valve resulting from degenerative valve disease. The hemodynamic effects of the regurgitation also appear to be mild, as Stitch does not have secondary dilation of either of his left heart chambers. As such, Stitch's mitral valve disease appears to be well-compensated, and, while I haven't seen his radiographs, Stitch's cardiac disease does not appear to be contributing to his cough or upper respiratory stridor.

**BREED**

Chihuahua Mix

No therapy is recommended based on this exam.

**SEX**

A recheck echocardiogram is recommended in ~6 months to monitor for disease progression.

**MN**

**AGE**

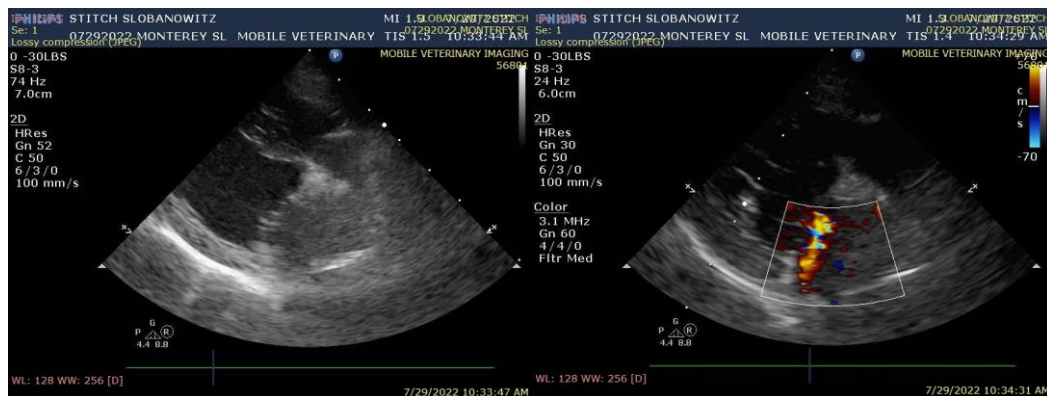
9 y

**WEIGHT**

12 lb

**HOSPITAL NAME**

Mobile Veterinary  
Imaging



The information and recommendations provided are based on the images presented by the referring veterinarian. No evaluation can be communicated regarding pathology that was not visible in the image/video clips provided.

**REFERRING VET**

Dr. Mitchell



Thank you for this referral. If the clinical or image interpretation does not parallel your findings or if I can be of any further assistance please contact me.

**DATE**

8/1/22

**Keith Blass, DVM, MS, DACVIM (Cardiology)**  
KeithBlass@gmail.com  
631-804-5754

**PERFORMED BY:**

Dr. Seth Mitchell

**INTERPRETED BY**

Keith Blass, DVM,  
MS, DACVIM  
(Cardiology)

**PATIENT**

Stitch Labanowitz

**SPECIES**

Canine

**BREED**

Chihuahua Mix

**SEX**

MN

**AGE**

9 y

**WEIGHT**

12 lb

**HOSPITAL NAME**

Mobile Veterinary  
Imaging

**REFERRING VET**

Dr. Mitchell